



2023年中間報告書

Good Holdings Corporation

関連プログラム

小児医療基金 (CMF - Children's Medical Fund)

このプログラムは、深刻な先天性欠損症と診断されたミャンマーとラオスの0～12歳の子供たちを対象に救命手術と医療の提供を行います。

活動実施者

Child's Dream Foundation
238/3 Wualai Road
T. Haiya, A. Muang
Chiang Mai 50100, Thailand

www.childsdream.org info@childsdream.org

Contents

Page

Executive Summary	1
1. Why We Do It	2
2. Updates	
○ Output analysis	2
○ Operational Updates	5
○ Outcome analysis	5
3. Financials	7
4. Case Highlights	7
i) Attachments	8

Vision

教育と権利を与えられた人々は、責任をもって次世代にとって公正・公平で健全な社会を形成し維持していくことができます

Mission

私たちは、不平等の影響を受けているメコン地域の子供や若者たちが健康的に成長でき、そして質の高い教育とより良い雇用機会を得ることができるようにするために存在しています。

私たちが行うことは全て、彼らが社会の平等で活動的なメンバーとして、権利を与えられ自分で決定できる生活を送れるようにするだけでなく、変化を導く責任あるリーダーになる可能性も生み出します。

Executive Summary

本レポートでは、2023年1月1日から6月30日までの小児医療基金(CMF)の主な最新情報を掲載しております。

報告期間中に、合計111件の新しい症例（110人の患者）がプログラムに受け入れ、67件の症例が終了し、そのうち82%が正常に治療されました。その結果、2023年は現在までに55人の命が救われました。

2023年1月には、このプログラムがタイの各地域に拡大され、医療ケアを必要とするより多くの子供たちに手を差し伸べることができました。治療を受けた患者の数は、新型コロナウイルス感染症流行前の同時期と比べて2倍に増加しております。

CMFが直接取り組む持続可能な開発目標（SDGs）



Child's Dreamが直接取り組む戦略目標



1. 私たちがサポートする理由：乳幼児死亡率と長期障害の削減

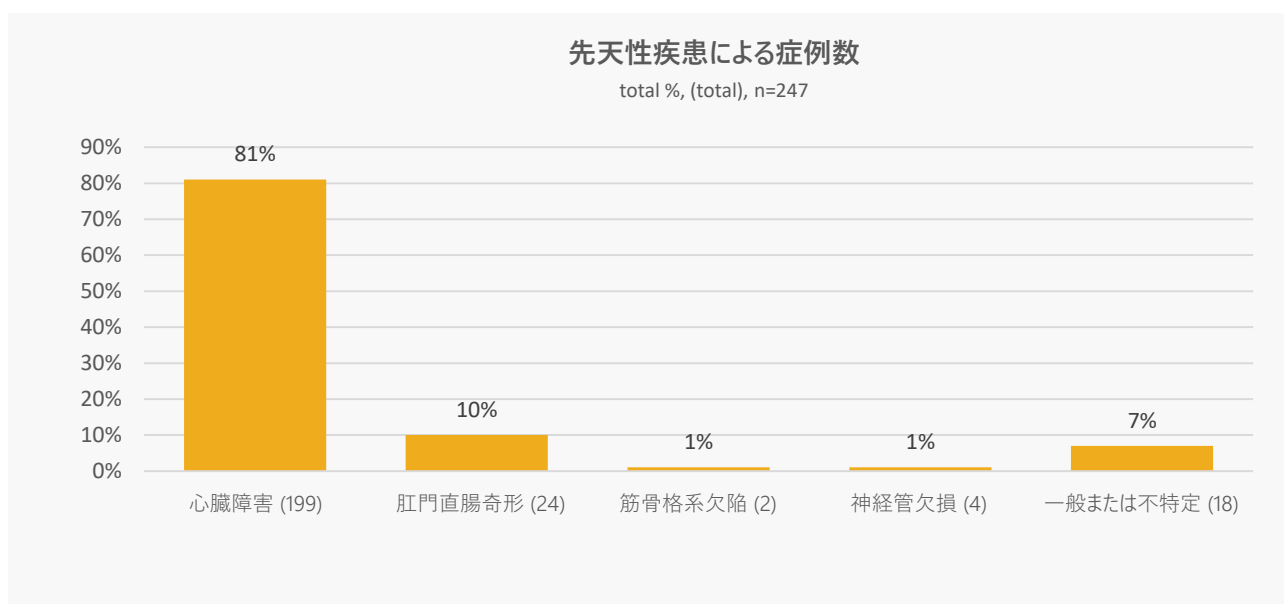
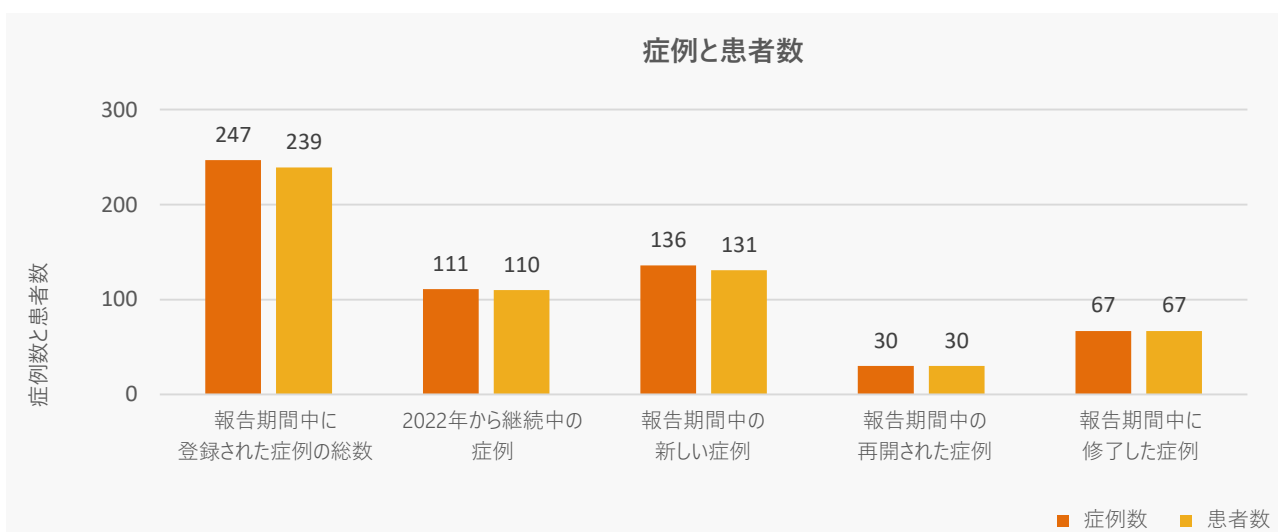
CMFは、2030年に向けた国連の持続可能な開発目標(SDGs)、特に「目標3：すべての年齢層の健康な生活を確保し、福祉を促進すること」をサポートするため、2006年の設立以来、乳幼児や子供に救命手術や医療提供を行っております。

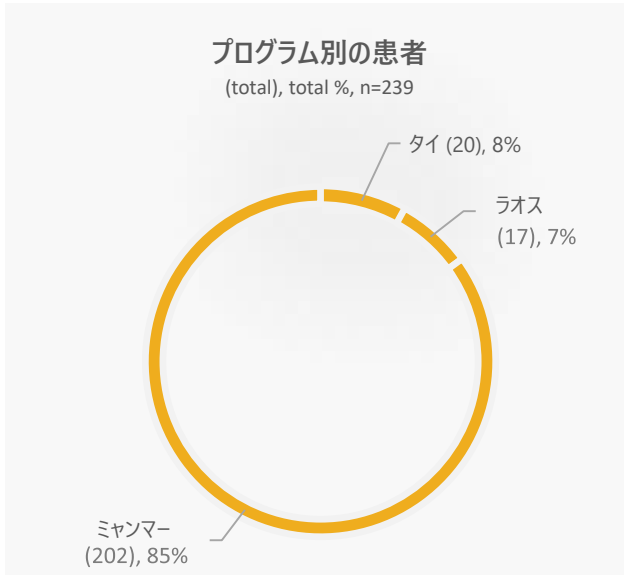
先天性疾患は乳幼児死亡の主な原因の1つであるため、医療サービスの推進ではその治療を優先しています。通常、外科的処置は費用が高額かつ複雑であるため、家族のだれもが手術はおろか必要な薬を買う余裕がありません。さらに、患者の多くがミャンマーから来ていますが、軍事政権による医療崩壊の危機でさらなる障害に直面しています。医療従事者達が軍事政権に反発しボイコットを起こしており、また利用できる医療ケアは高額となっているのです。

医療ケアを必要としている患者は心臓疾患、肛門直腸奇形、神経管欠損と診断された0～12歳の子供たちです。経済的支援や質の高い医療提供がなければ、これらの子どもたちのほとんどは早期に死亡するか、障害によって不自由になり学校に通うことができず、貧困の連鎖が続いてしまうことになります。

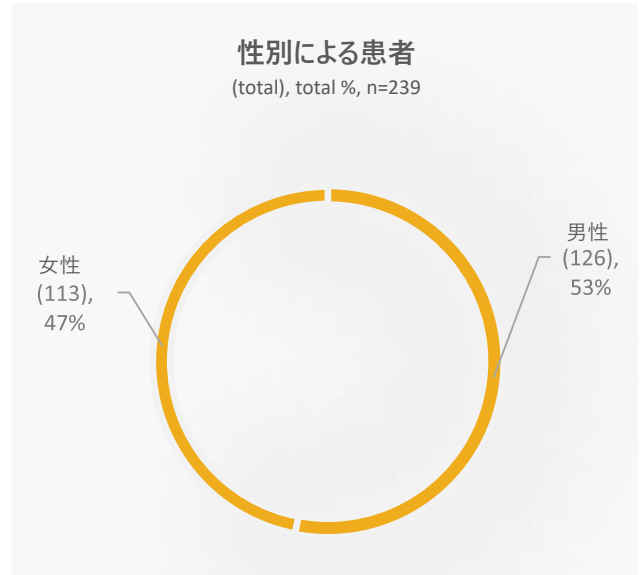
2. 更新情報 - 2023年1月～6月

評価グラフ

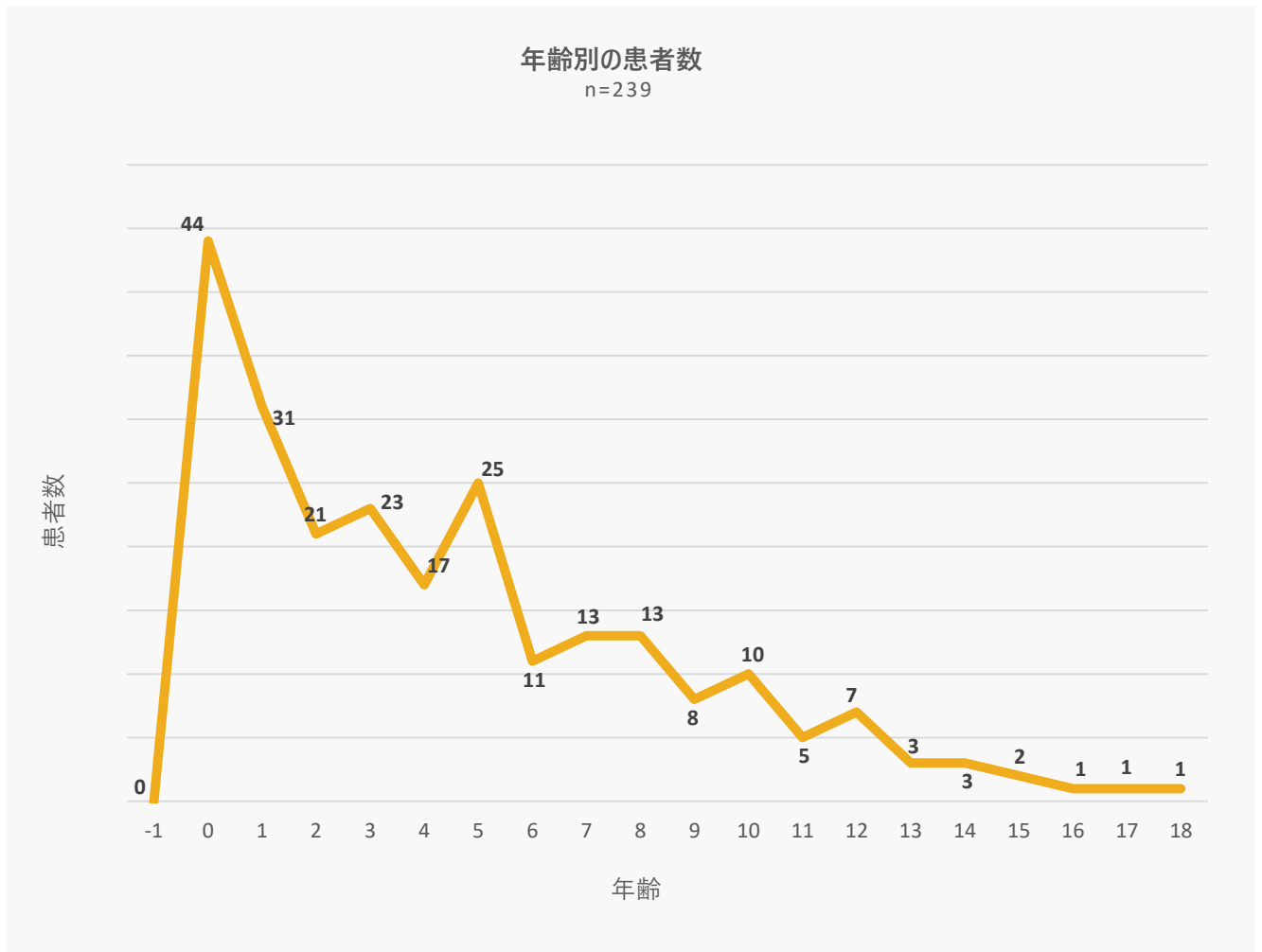




報告期間中の出身地別患者数

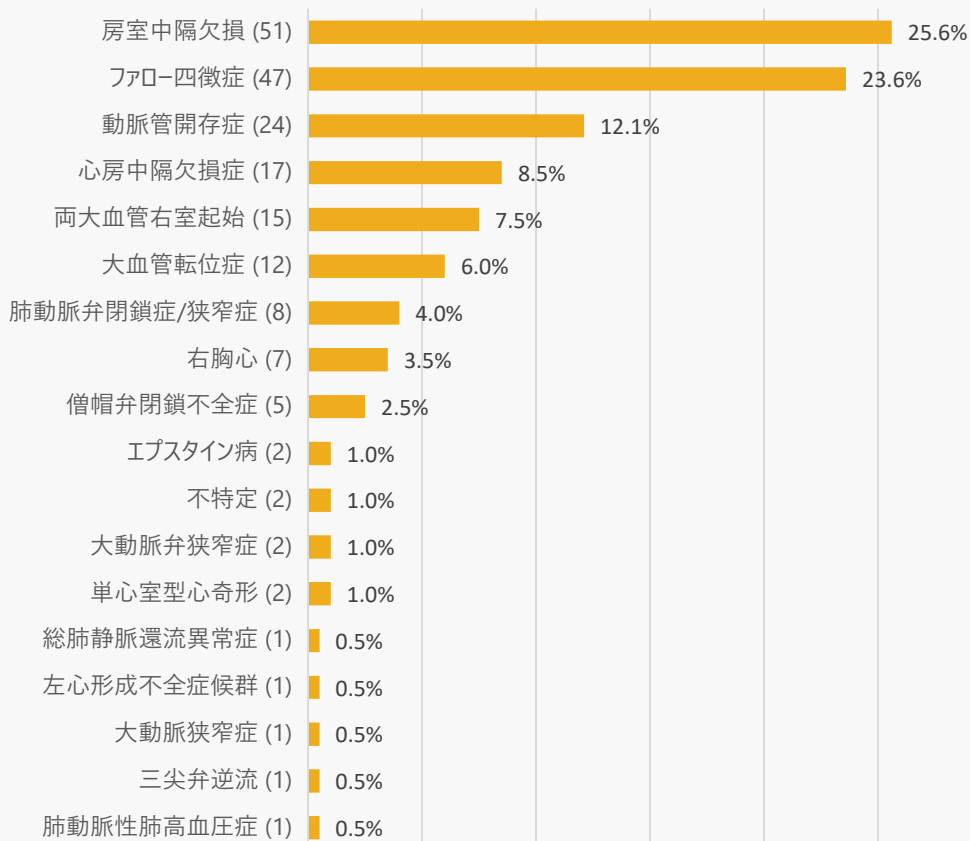


報告期間中の性別による患者数



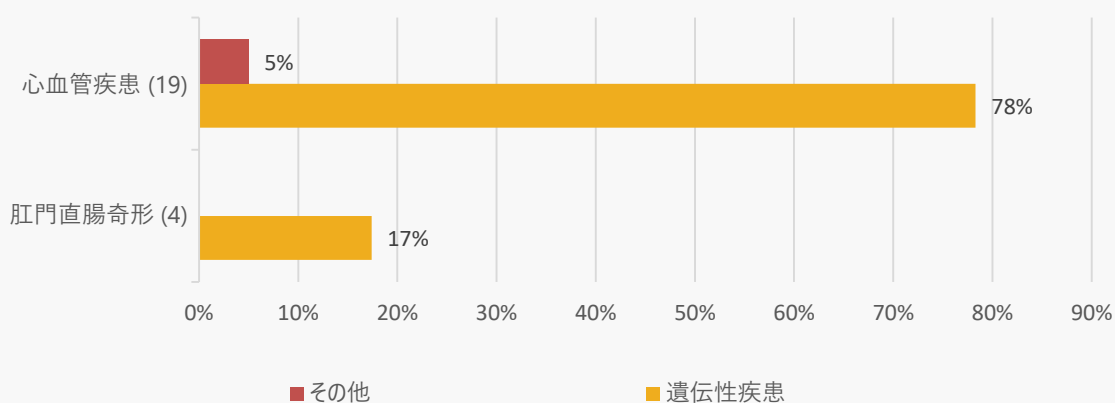
種類別の心臓障害の症例数

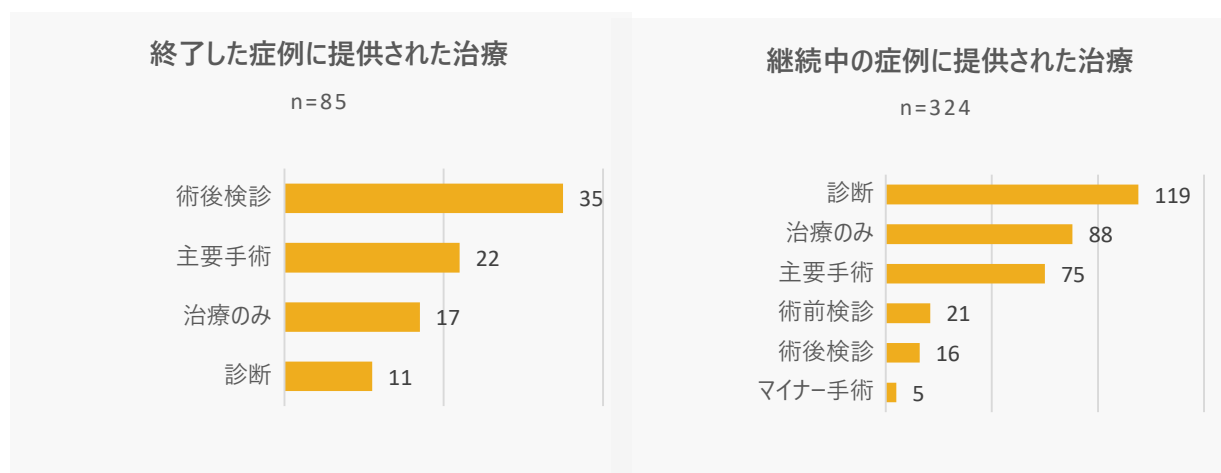
(total), total %, n=199



併存症のある症例の数

(total), total %, n=24

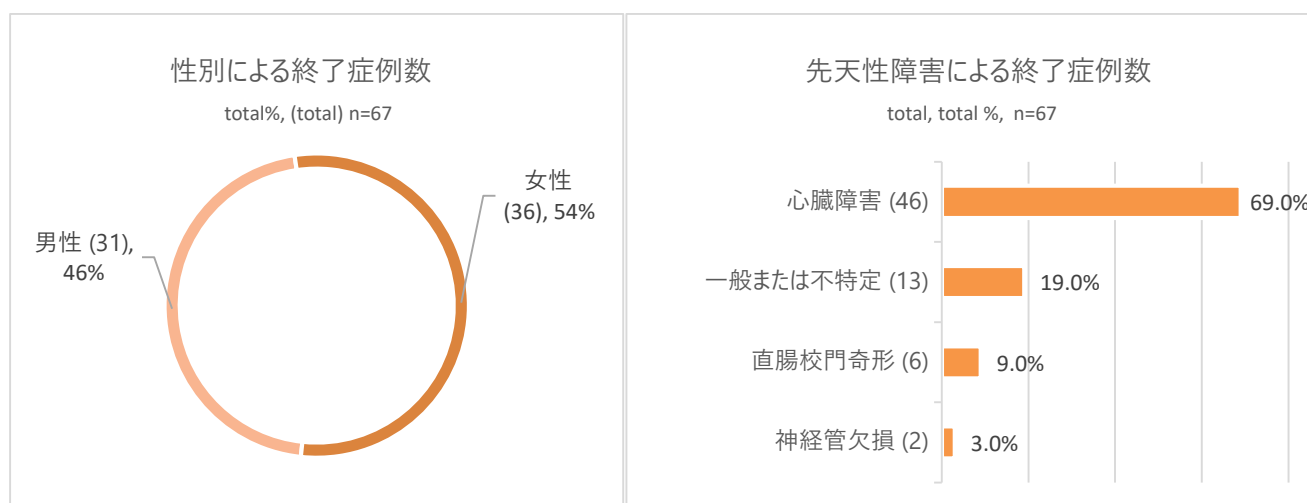


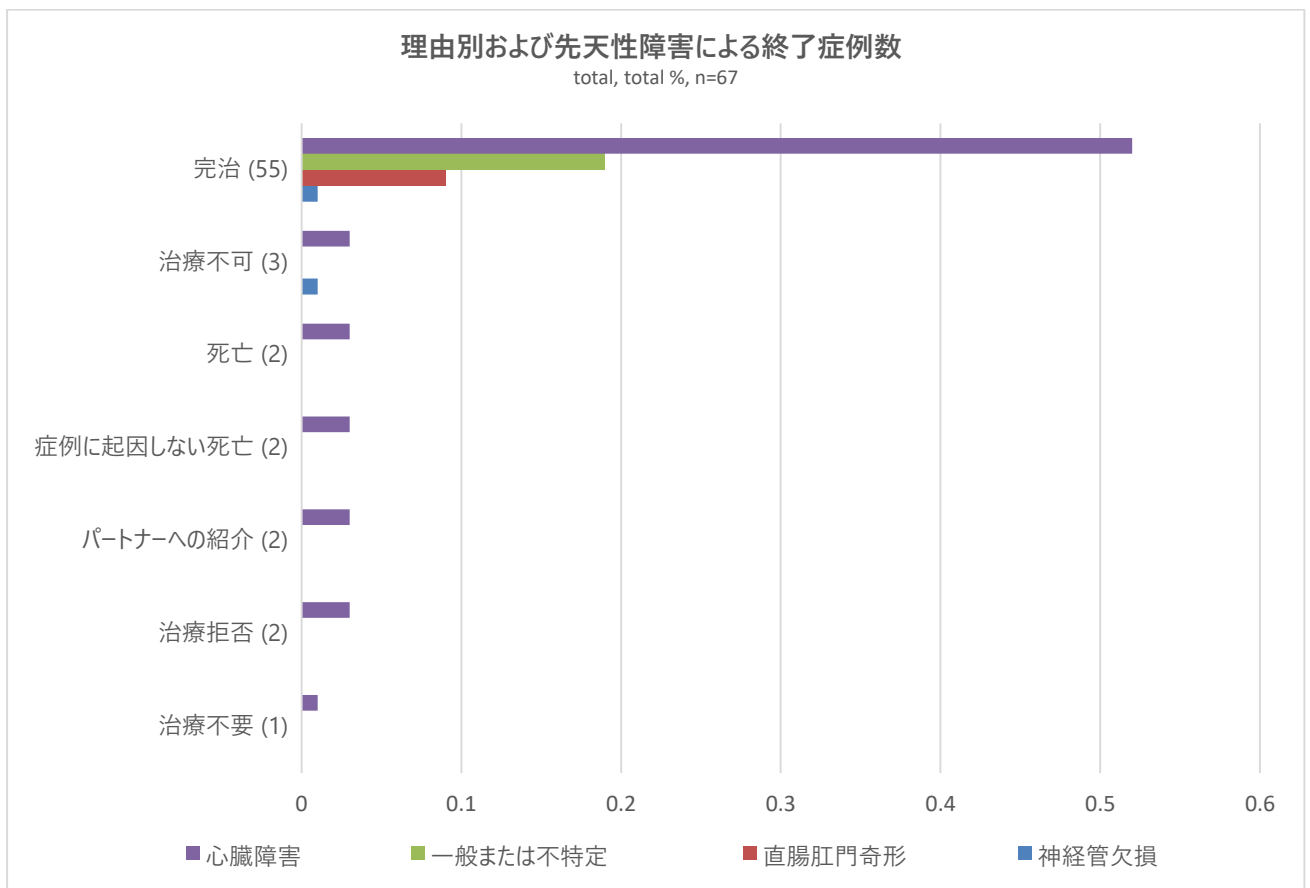
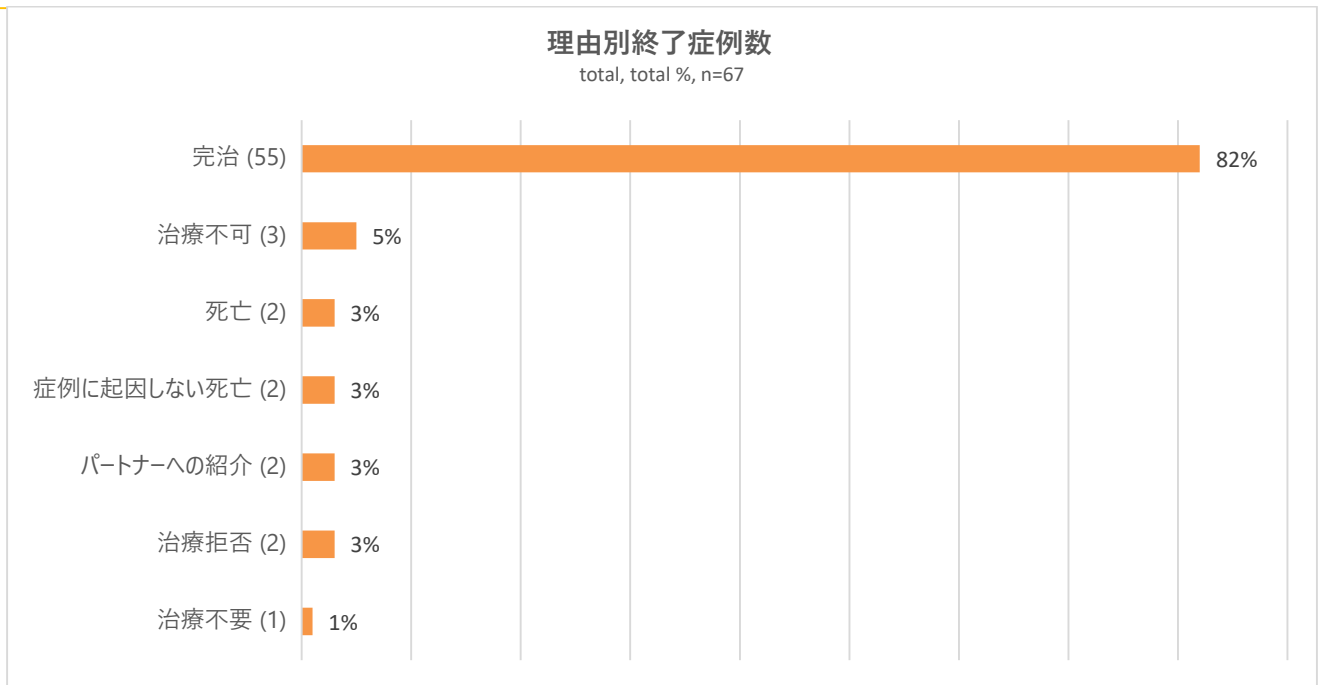


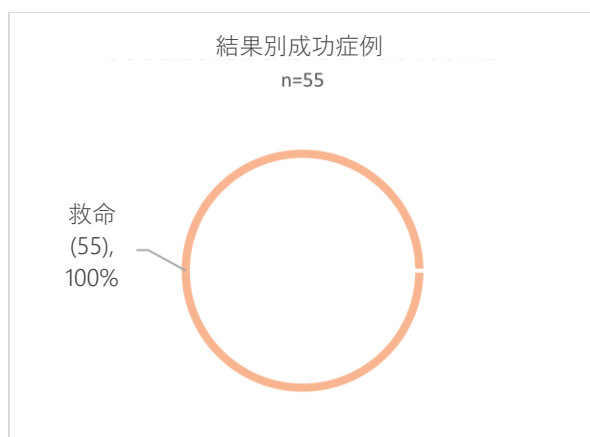
主な活動 - 2023年1月～6月

- 2023年は現在までのところ、プログラムは中断することなく通常通り実行しております。
- CMFの新規患者受け入れ数は、新型コロナウイルス感染症流行前の同時期と比べて2倍に増加しました。この増加により、チェンマイ大学病院での待ち時間も増加しました。
- 患者数の増加はプログラムの拡大に部分的に関係しており、現在タイ各地で様々な事業を展開しておりますが、依然としてミャンマーからオスの患者、またはタイの難民キャンプからの患者のみに治療をおこなっております。展開している事業内容は次の通りです。
 - 私たちはバンコクで2つのパートナー組織と協力しており、これらの組織はタイ中部の対象コミュニティと協力しています。これによりチェンマイ大学病院での待ち時間が軽減されます。
 - 私たちは、タイ北部にあるターク県のメーソート病院で心臓患者を検査するための移動診療所を運営している小児心臓手術基金(PCSF)およびタイの心臓疾患小児基金(TCCF)と協力しています。
 - 合併症のない症例はすべてバンコクで手術を受けます。複雑な症状を持つ患者は長期にわたる治療が必要なためチェンマイのCMFセーフハウスに滞在し、治療と手術を受けます。
 - CMFにバンコクの患者の受け入れ対応のため、1名の新しいスタッフが加わりました。

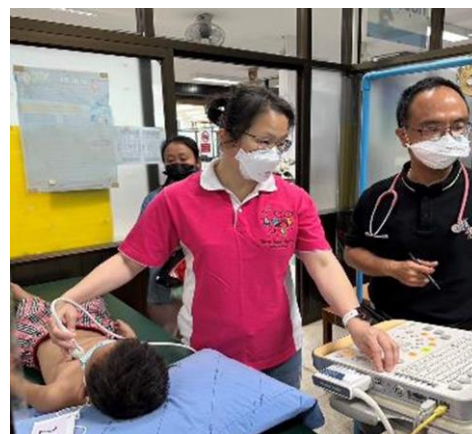評価グラフ







成功症例は“救命”または“生活改善”のいずれかに分類されます。この報告期間における成功症例は、すべて救命処置でした。



2023年1月に、パートナー組織との連携が開始されました。

3. 財務

報告期間中に、CMFは4%の管理諸経費を含む合計468,980米ドルを費やしました。総支出の90%は治療と手術に使用され、食費が3%、介護者の宿泊費および交通費と、その他関連経費が3%という内訳です。

財務詳細については2024年1月の年度末レポートで再度ご報告いたします。

4. 事例要約

次ページからは、タイ人スタッフが作成した患者症例管理システムより抜粋した患者レポートを掲載しております。一部英語の内容に不備がございますが、ご理解いただける範囲のものと判断し、原文のまま掲載しております。

この場をお借りして、皆様のご支援やご信頼に心からの感謝を申し上げます。

困難に直面しているCMFの患者やその家族にとって、まさに重要な時期であり、私たちが力を合わせることでさらに多くの子どもたちの生活に大きな影響を与えることができます。

国境が再び開放され、救命サービスの需要増加によりプログラムを拡大し、2023年の予算は100万ドルに増加いたしました。今後も皆様の貴重なご支援を賜りますようお願い申し上げます。なお、この高額な予算の確保の見通しはまだありません。

チェンマイより、2023年8月7日

Child's Dream Foundation

Marc T. Jenni
Founder & Managing Director Operations

Daniel M. Siegfried
Founder & Managing Director Programmes



Patient No: 9921

CASE SUMMARY REPORT

Patient name: Wan Yi Phone

Sex: Male

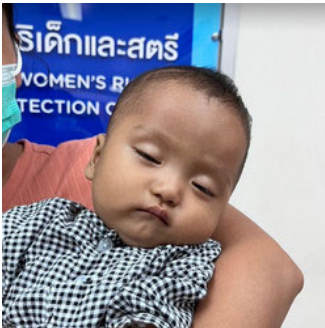Date of birth: 27 March 2022

Hospital Nr: 4138195

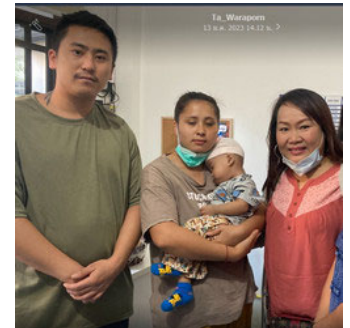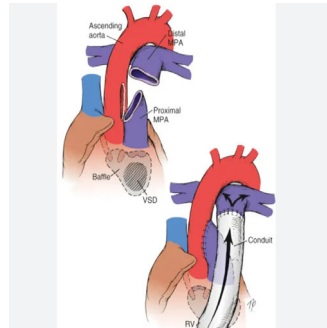
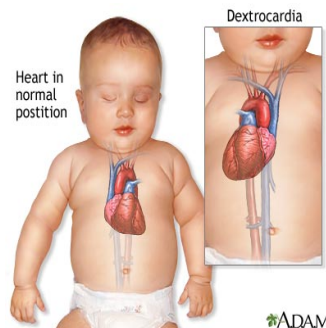
Date of submission: 14 September 2022

Date of closure: 06 February 2023

Final diagnosis: Cardiac disorder - Dextrocardia



Pre-treatment



Post-treatment

Pre-treatment profile

He was born at a private hospital in Lashio, Shan state, Myanmar. He was born like a normal baby. When he was two months old, his mother noticed that he had shortness of breath and was slightly blue when he cried. His parents took him to the provincial hospital, where he was diagnosed with heart disease and told that surgery was required. His father heard that the healthcare in Thailand was good and that his son could be treated there. He borrowed money from relatives and neighbours to prepare his passport and surgery costs. He had THB 130,000. His parents brought him to Chiang Rai Hospital, Thailand. There, the doctor told them that he could not perform his surgery in Chiang Rai because his condition is complicated and risky. The doctor gave his parents the referral letter to Chiang Mai University Hospital for proper case management. At Chiang Mai University Hospital, the social worker requested support from Child's Dream because he did not have any health insurance in Thailand and the cost was around THB 500,000. His parents could not afford it for him.

Post-treatment profile

Wan Yi Phone's father says "Thank you very much for your kindness to support my son's treatment. I will keep Child's Dream organisation in my mind. I will tell my son when he is growing up about your support. We were worried about our son's health. He had severe fatigue, respiratory infection, difficulty breathing, periodic fevers, and cyanosis. Currently, he looks good, is active, and sleeps and eats well. Four months in Chiang Mai gave new life to my son. We will go back home with the Wan Yi Phone's stronger heart. He will attend school and have a beautiful future as a normal child. If he wants to be a doctor, I will support him as I can. On behalf of my family member, I would like to thank you very much to the donor who gave us new life, and all staff who support us all the time if we requested. We wish you all good health, happiness, and peace."

Procedures

Date	Treatment information
12 September 2022	First consultation, echo shows multiple defects. Doctor plan do CTA
19 September 2022	Admit for CTA, CAG and treat RSV pneumonia
06 December 2022	Admit for total correction, Stenotomy to Rt.ventriculotomy to intraventricular tunnel patch baffle 8/12/22 with out post-op complications.
09 January 2023	Follow up, his condition is good. He needs continue take medicine for reducing his pulmonaty hypertension. Parents could support for post op treatment.

16 January 2023

Follow up, his pneumonia is solved. His parents will return home and follow up at Chiangrai hospital

Total cost

Medical cost USD 9,484.34

Non-medical cost USD 635.02

Administration cost USD 183.12

Overhead USD 721.17

Total cost USD 11,023.66

Estimated cost USD 14,667.06

Child's Dream Foundation

238/3 Wualai Road, T. Haiya, A. Muang, Chiang Mai 50100, Thailand

Email: info@childsdream.org • Website: www.childsdream.org • Tel. +66 (0) 53 201 811 • Fax +66 (0) 53 201 812



Patient No: 9601

CASE SUMMARY REPORT

Patient name: Bible Chit

Sex: Male

Date of birth: 01 August 2018

Hospital Nr: 3957462

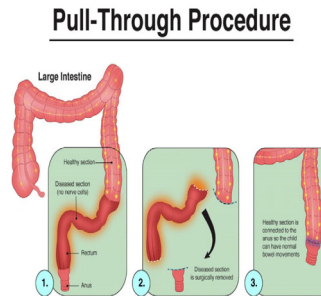
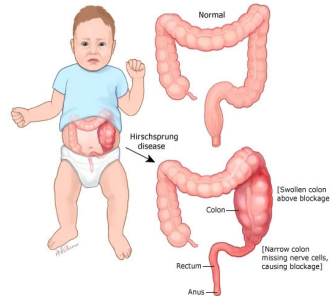
Date of submission: 04 September 2019

Date of closure: 02 June 2023

Final diagnosis: Anorectal malformations - Hirschsprung's disease



Pre-treatment



Post-treatment

Pre-treatment profile

Bible Chit is a one-year-old boy who lives with his parents and a five-year-old sister in Myawaddy Township, Karen State, Myanmar. His mother is a homemaker and his sister goes to kindergarten at their village school. Currently, his father works as a farmer and he has to rent land to grow corn and beans. After harvest, he is able to make around 30,000-40,000 baht (approx.1,000 -1,300 USD) in a year.

He was born without any complications at Mae Tao Clinic (MTC). Five days after they went home, he vomited the whole night and was able to pass less stools. In the morning, his mother noticed that Chit's abdomen was increasing in size and his mother decided to take him back to MTC. The next day, the medic referred him to Mae Sot Hospital, Thailand, where the doctor diagnosed him with Hirschsprung's disease. The next day, the doctor performed surgery, moving the colon to the peritoneal. His treatment was paused for three years during COVID-19 because the border was closed. In 2023, the border was reopened, he went to Mae Sot Hospital where the doctor gave him the referral letter for receiving definite surgery in Chiang Mai.

Post-treatment profile

His mother said "Before the last surgery, it's not easy to change the dressing around the hole in his stomach, when he has diarrhea. Sometimes, I really feel stressed out and I am disappointed [that he was born with all these problems] as we do not have enough money even for necessities. Sometimes we have to buy cotton to change the dressing frequently [which is expensive]. And I have to give all my time to him, and I cannot help my husband on the farm at all. However, we are praying for him and we worry a lot about him. When he was admitted in the hospital for the last surgery, I was very happy to see him as a normal boy. People around me blamed me for his abnormality. I felt guilty and tried my best to take care of him. Now, I am very happy with his condition. We will go back home with a new Bible Chit. I want him to be healthy and when he grows up, I want him to become a pastor. I am very happy that my son received the chance to have treatment. If he had not, we would never be able to afford to treat him. Now, I feel like something heavy that I had to carry, has disappeared. We would like thank the donors and all involved staff both in Mae Sot and Chiang Mai."

Procedures

Date	Treatment information
09 September 2019	First consultation, plan do BE
12 November 2019	Admit for BE but he had food hand mounth disease
13 February 2020	admit for BE
01 July 2022	get new app
20 August 2022	Admit for Duhamel operation with appendectomy. Dilate anus with candle no 12 BID.
12 September 2022	f/u, his wound is not good, need dressing every 2-3 days.
19 October 2022	Post op check up, abdominal wound is good. Dilate anus no. 18, twice a day, for 1 month.
14 November 2022	Follow up, his condition is well. Dilate anus with candle no.18 BID in Nov & Dec. Dilate OD in Jan - Feb 23. Dilate EOD in Mar - Apr 23. However, if his condition is well, he doesn't need come back to CM in May.
15 May 2023	Mother called staff to inform about the patient's condition is good. So they don't need to come back to CM.

Total cost

Medical cost	USD 3,310.79
Non-medical cost	USD 1,341.30
Administration cost	USD 585.64
Overhead	USD 366.64
Total cost	USD 5,604.38
Estimated cost	USD 3,520.09

Child's Dream Foundation

238/3 Wualai Road, T. Haiya, A. Muang, Chiang Mai 50100, Thailand

Email: info@childsdream.org • Website: www.childsdream.org • Tel. +66 (0) 53 201 811 • Fax +66 (0) 53 201 812



Patient No: 9901

CASE SUMMARY REPORT

Patient name: Aung Hein San

Sex: Male

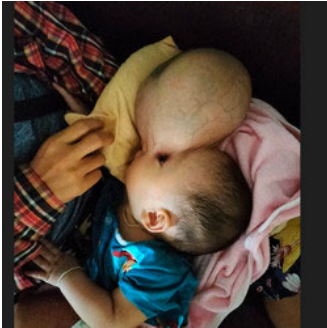
Date of birth: 28 November 2021

Hospital Nr: 4133091

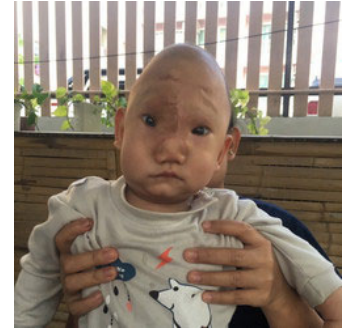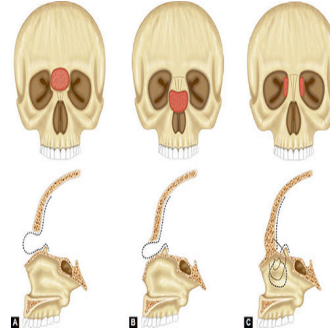
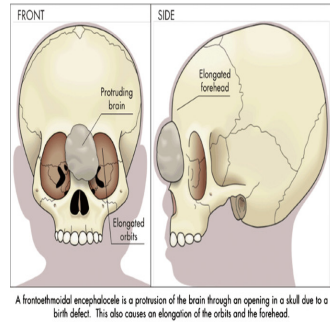
Date of submission: 10 August 2022

Date of closure: 06 February 2023

Final diagnosis: Neural Tube Defects



Pre-treatment



Post-treatment

Pre-treatment profile

The child was born to ethnic Karen parents in Karen state, Myanmar. Like many other families, the parents make their earnings through buying and selling local products. There is a small farm belonging to the family. Sometimes, the family receives financial support from relatives working and living abroad. The income is not regular and the family is struggling to make ends meet. Meanwhile, their child developed swelling in the nose region at the age of 4 months. The swelling became larger gradually and extended up to the forehead covering half of the forehead. While looking for options for the child's health in the Myanmar side, the family found it difficult to live in their place as the armed conflict in their area escalated since December 2021. Considering the danger to their lives due to security reasons, the whole family decided to take refuge in Maela camp while fleeing from their village of origin on the Karen side. The family then approached the refugee camp health hospital for an initial consultation and potential support. An IRC staff member referred him to Child's Dream for supporting the costs of medical care.

Post-treatment profile

Her mother says "I would like to say a million thanks to the donor, IRC and Child's Dream Foundation. You gave us a new baby. Since he was born and the sac was growing up dramatically, we couldn't sleep and tried to get money to treat him. He could not lift his head up, and also could not sit. We left our hometown, were hopeless, and always had air strikes, gun fire, and fighting. We feel safer in the Maela refugee camp, although we have no job, and no opportunity to get money, but we get donations from the Thai government and international organizations. I hope that my hometown will have peace soon. I want to go back home."

Procedures

Date	Treatment information
11 August 2022	First consultation, she has appointment with plastic surg.
12 August 2022	She has fever, crying all the time, take patient to ER. Doctor prescribed her medicine.
11 August 2022	Surgeon give Sx schedule.
05 September 2022	S/P.excision FEEM with skin and soft tissue coverage 7/9/22. Post op she had fluid like CSF fluid leakage. Doctor set OR on next day for VP shunt. S/P. Rt VP shunt with left parental VP shunt 8/9/22

27 September 2022 Neuro Sx give him post op follow up on 21/10//22
11 October 2022 Post op check up & stitches off. Her wound is good. No need dressing wound. VP shunt has something wrong, he need visit neuro doctor.
17 October 2022 f/u, his condition is good.
13 December 2022 Follow up, his condition is well. Close him from program.
27 January 2023 Post op check up, his condition is well. No need follow up wth neuro-surg. Plastic surgeon will perform his surgery when he is 15-17 years old.

Total cost

Medical cost	USD 5,470.70
Non-medical cost	USD 604.61
Administration cost	USD 148.71
Overhead	USD 435.68
Total cost	USD 6,659.69
Estimated cost	USD 7,333.53

Child's Dream Foundation

238/3 Wualai Road, T. Haiya, A. Muang, Chiang Mai 50100, Thailand

Email: info@childsdream.org • Website: www.childsdream.org • Tel. +66 (0) 53 201 811 • Fax +66 (0) 53 201 812